



CEEA 5: Neuromišićna blokada, regionalna anestezija i
terapija bola

BLOKOVI NERAVA GLAVE I VRATA

Date: 02.03.2018.

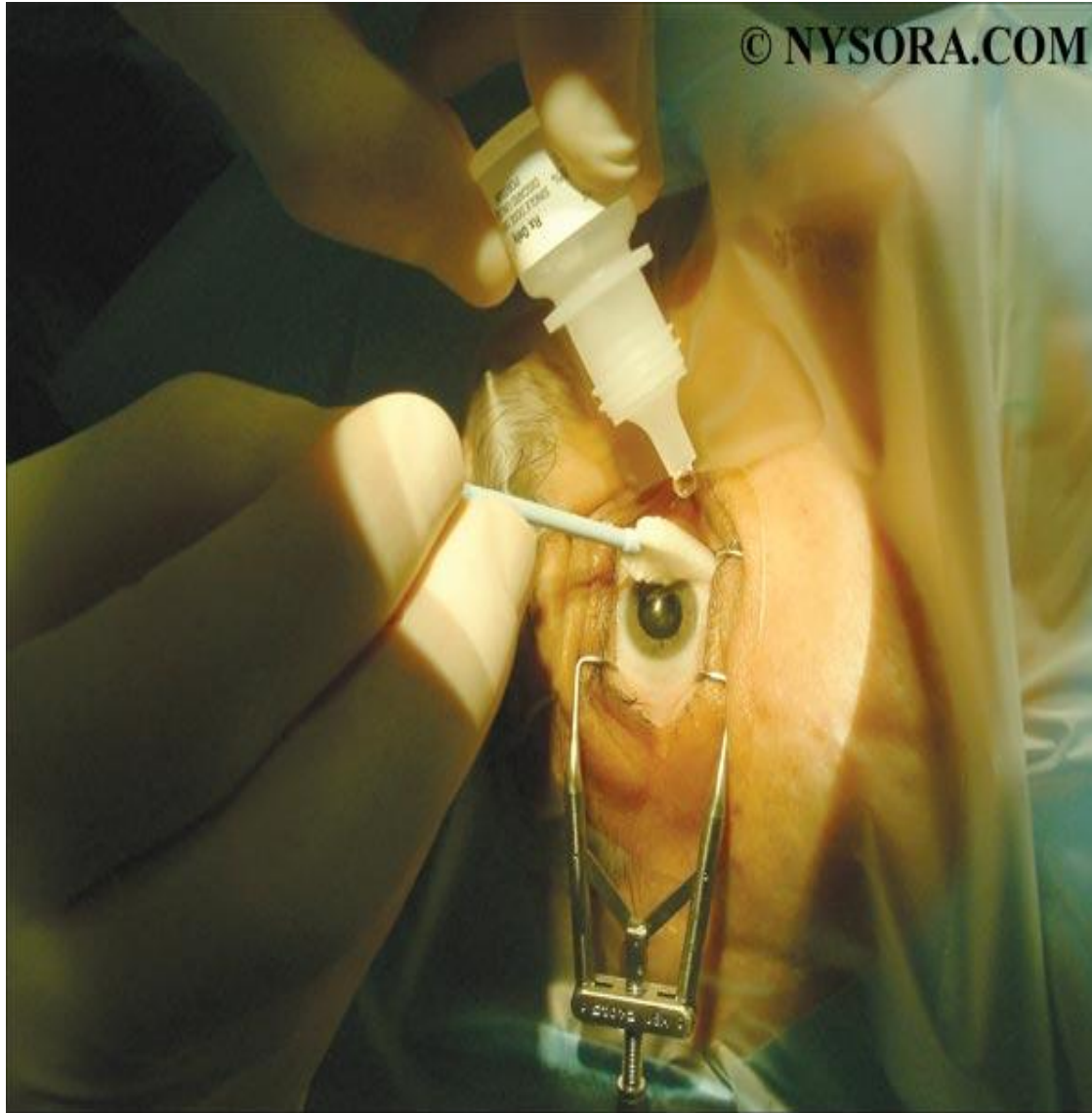Language: Serbian

City: KOPAONIK

Country: Serbia

Speaker: **ass. dr sci med Dejan Marković**

CEEA Topikalna anestezija

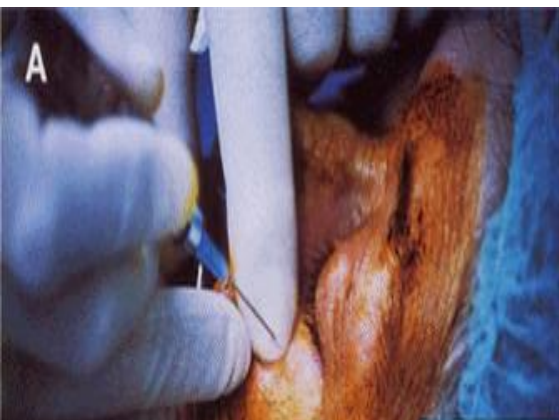


Proparacain 0,5%
Procain 1%, 2%
Etidocain 1%
Oxybuprocain 0,4%
Lidocain 1%
Prilocain...

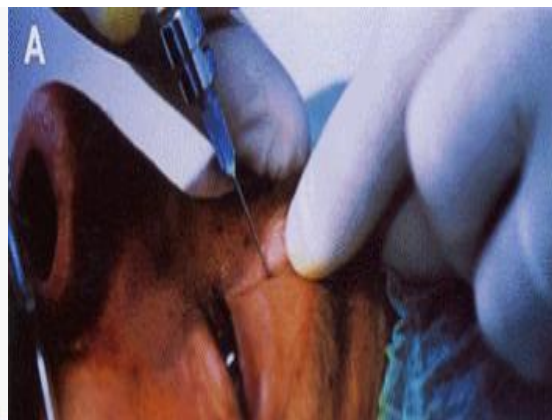Peribulbarni blok

inferotemporal periconal

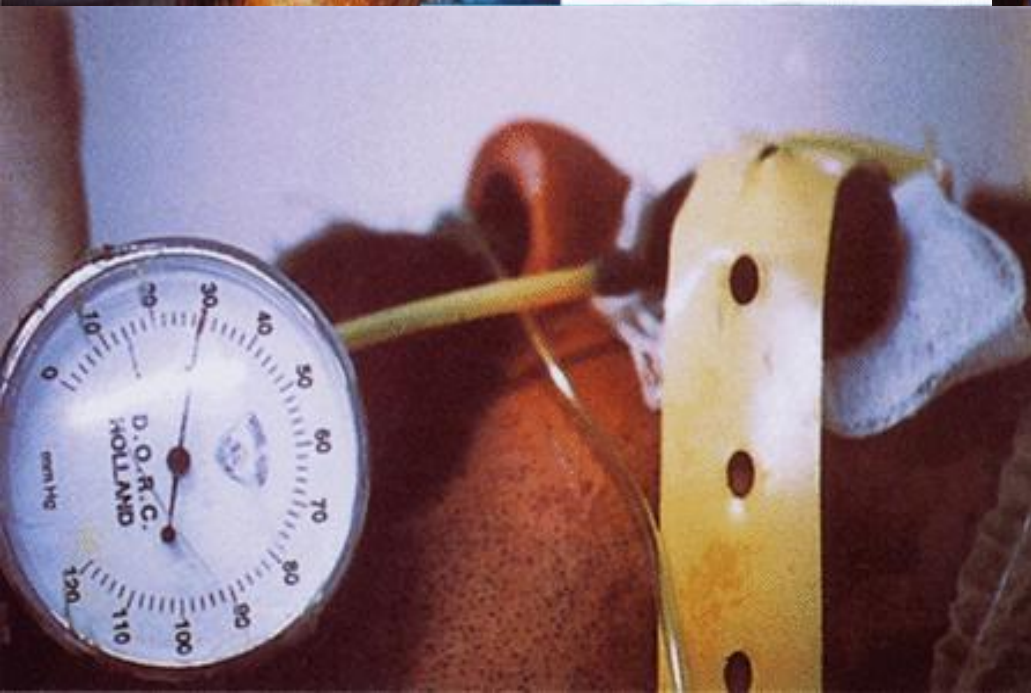
superonasal periconal



6 do 8 ml




2 do 4 ml



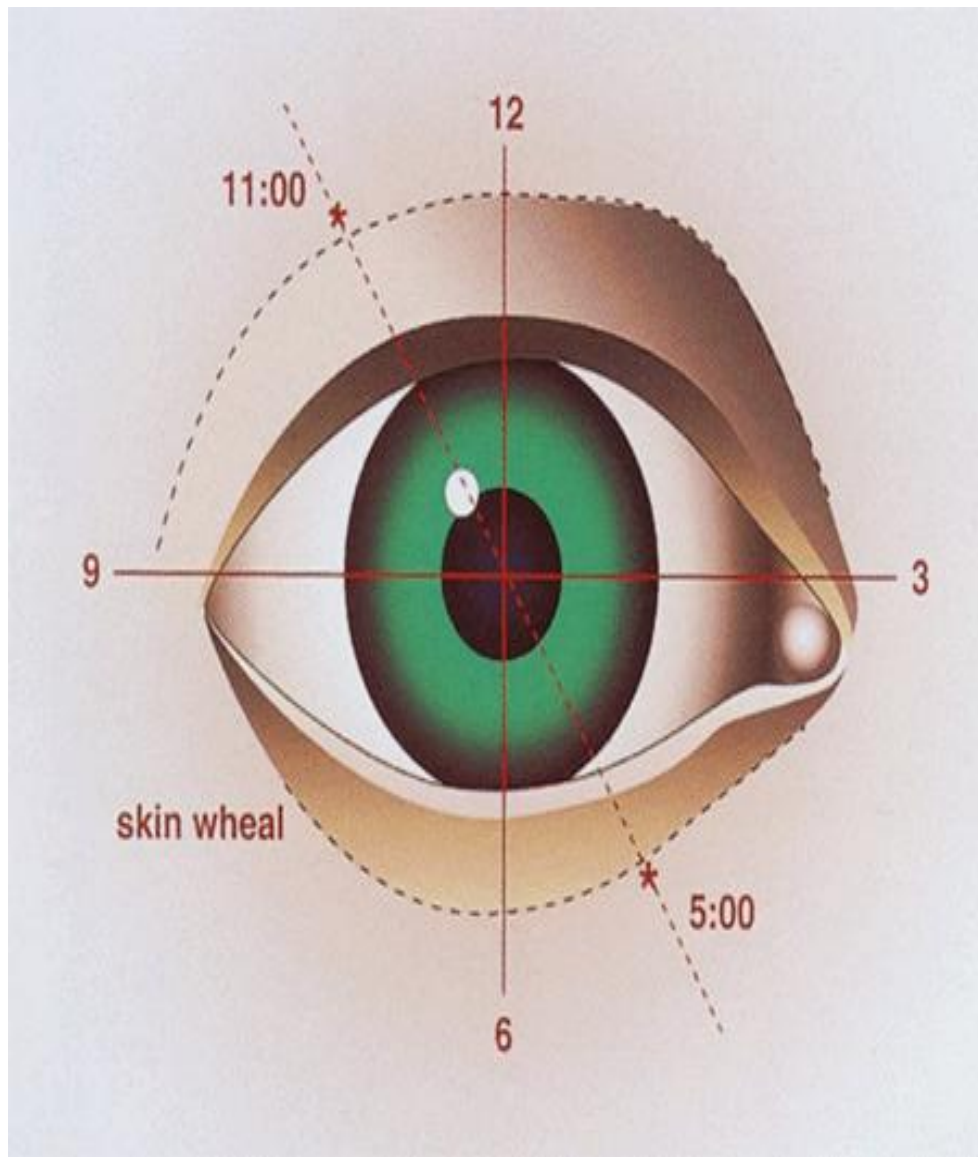
Igla:

22 G

25 mm



Retrobulbarni blok

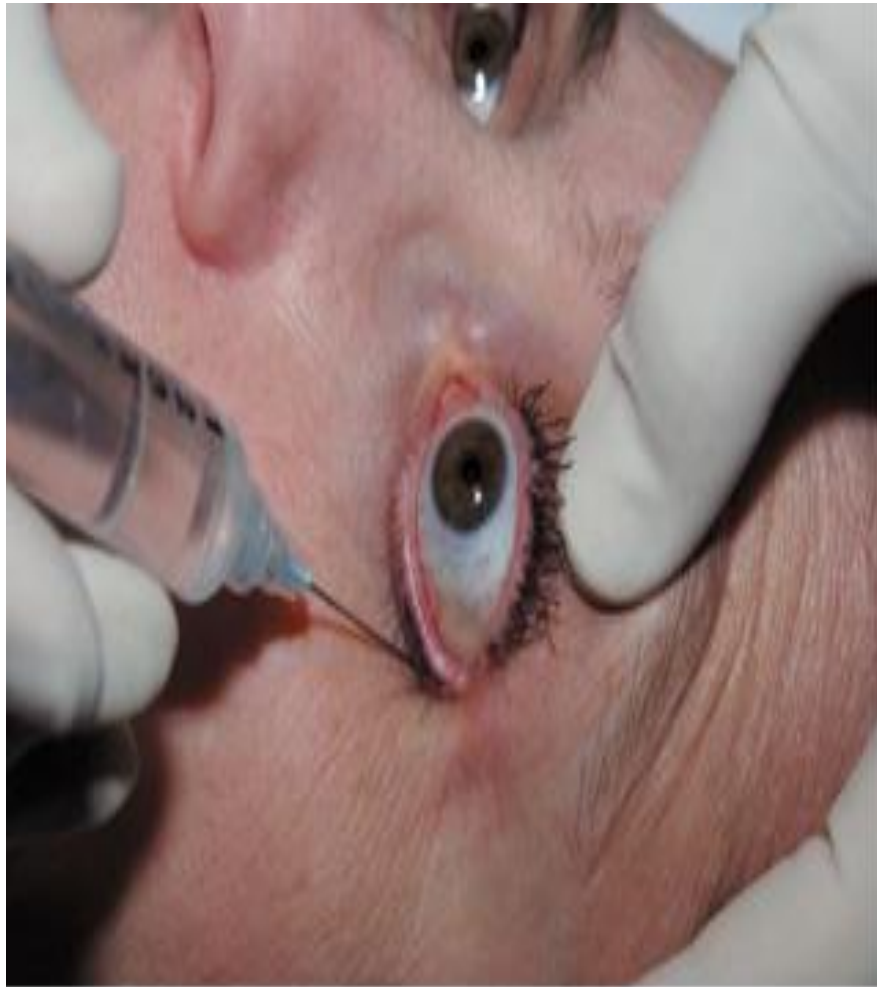

2 ml plus 5 do 7 ml LA

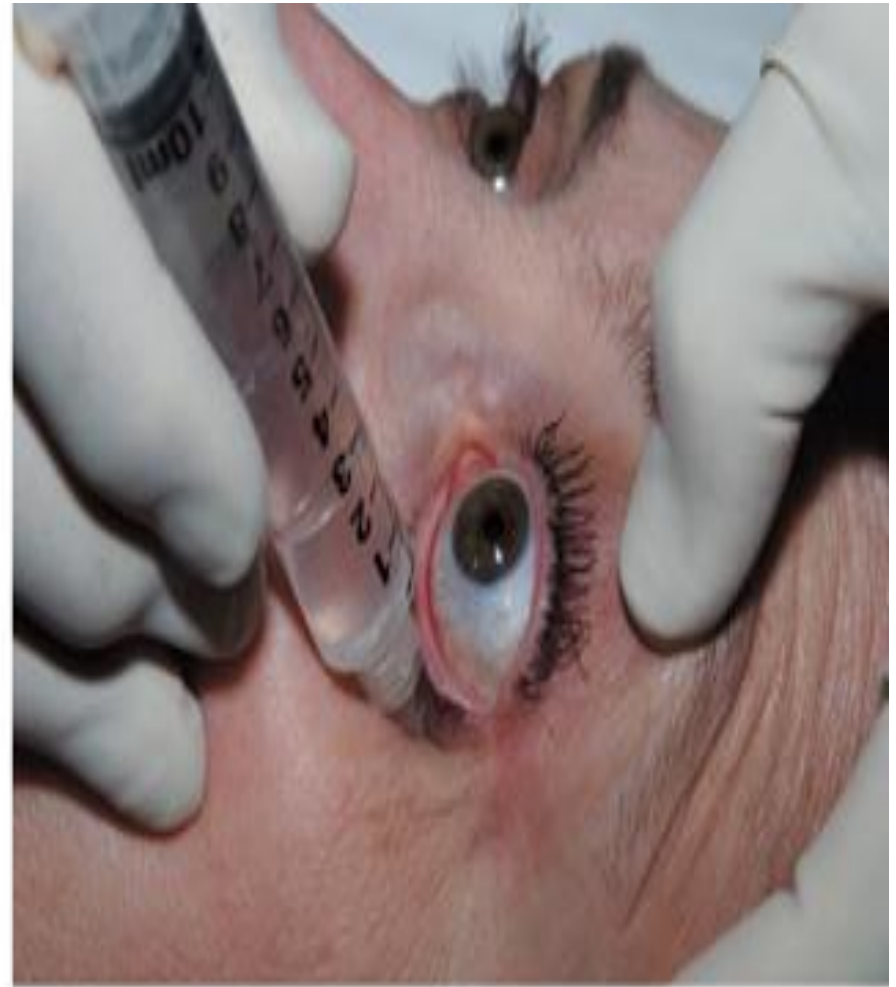Igla:

27 G 31-mm

Retrobulbarni blok



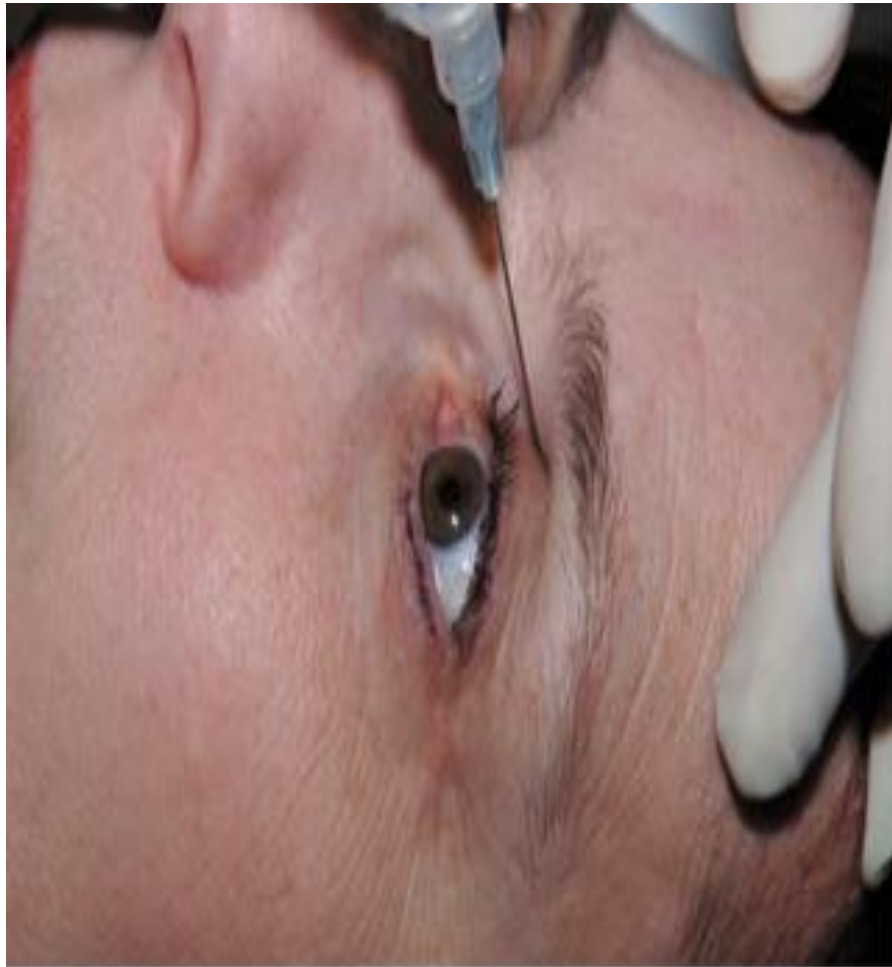A



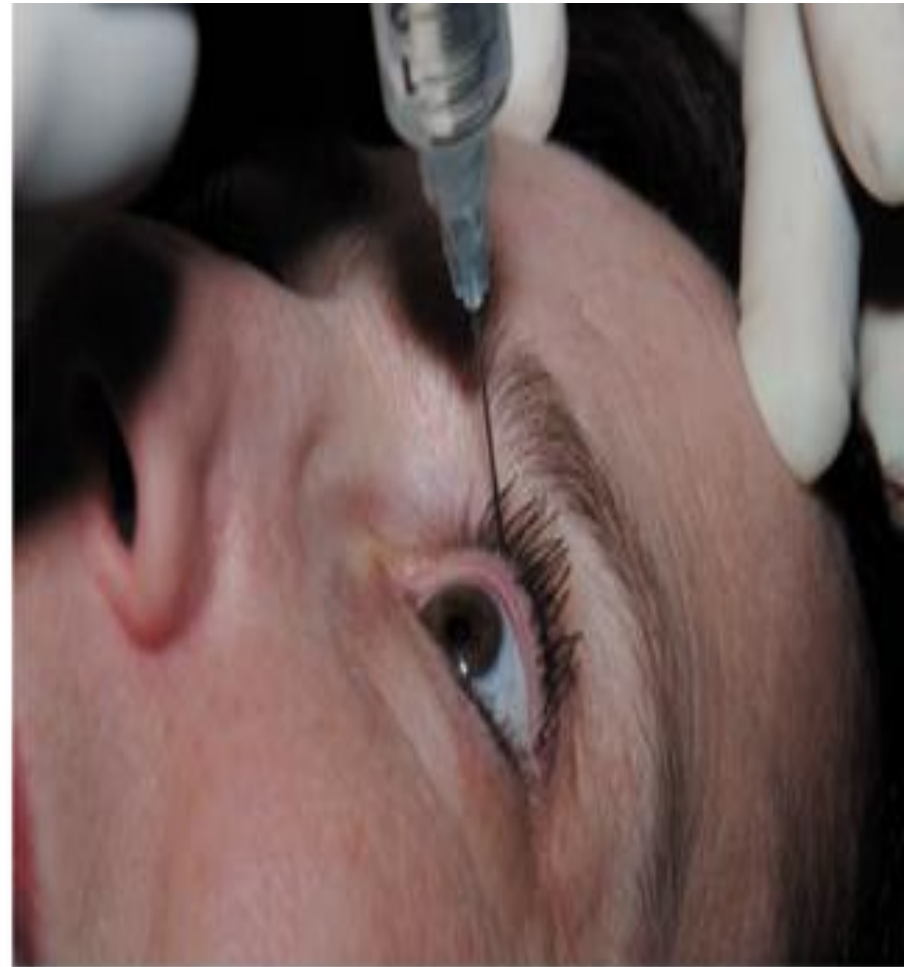B

Copyright © 2009 Wolters Kluwer Health | Lippincott Williams & Wilkins

Retrobulbarni blok



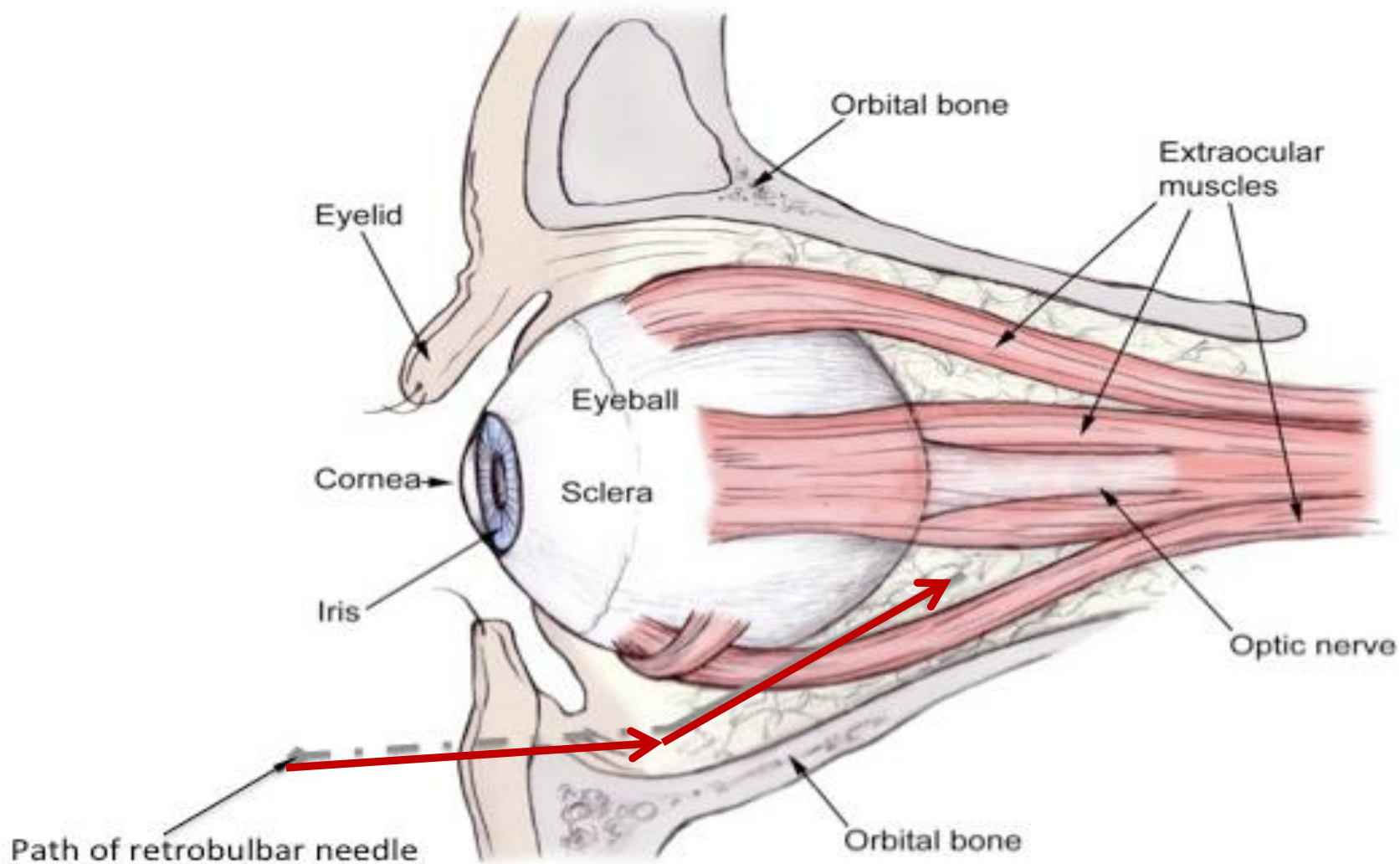
A



B

Copyright © 2009 Wolters Kluwer Health | Lippincott Williams & Wilkins

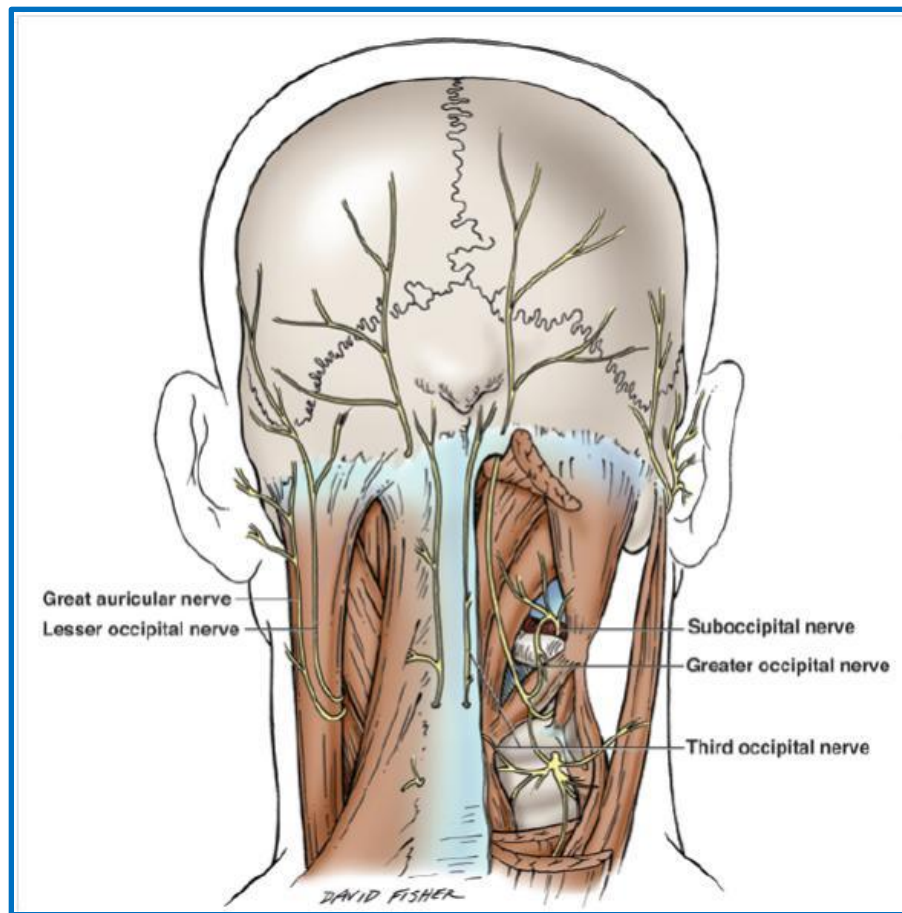
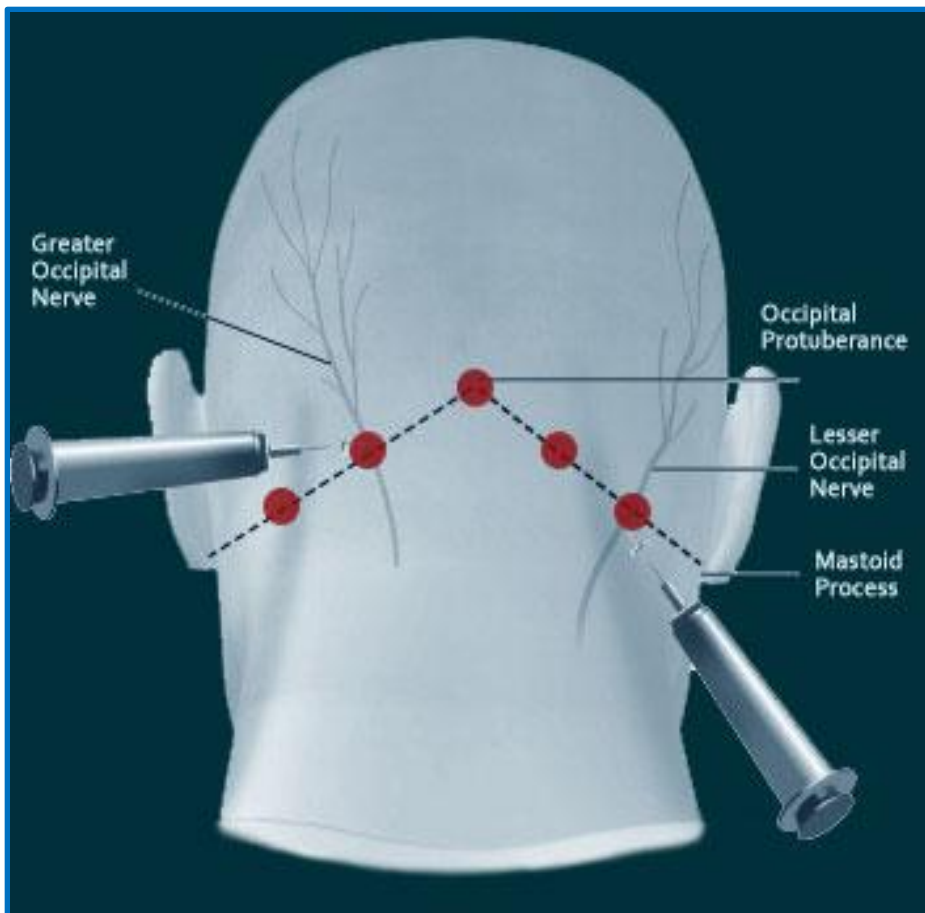
Retrobulbarni blok



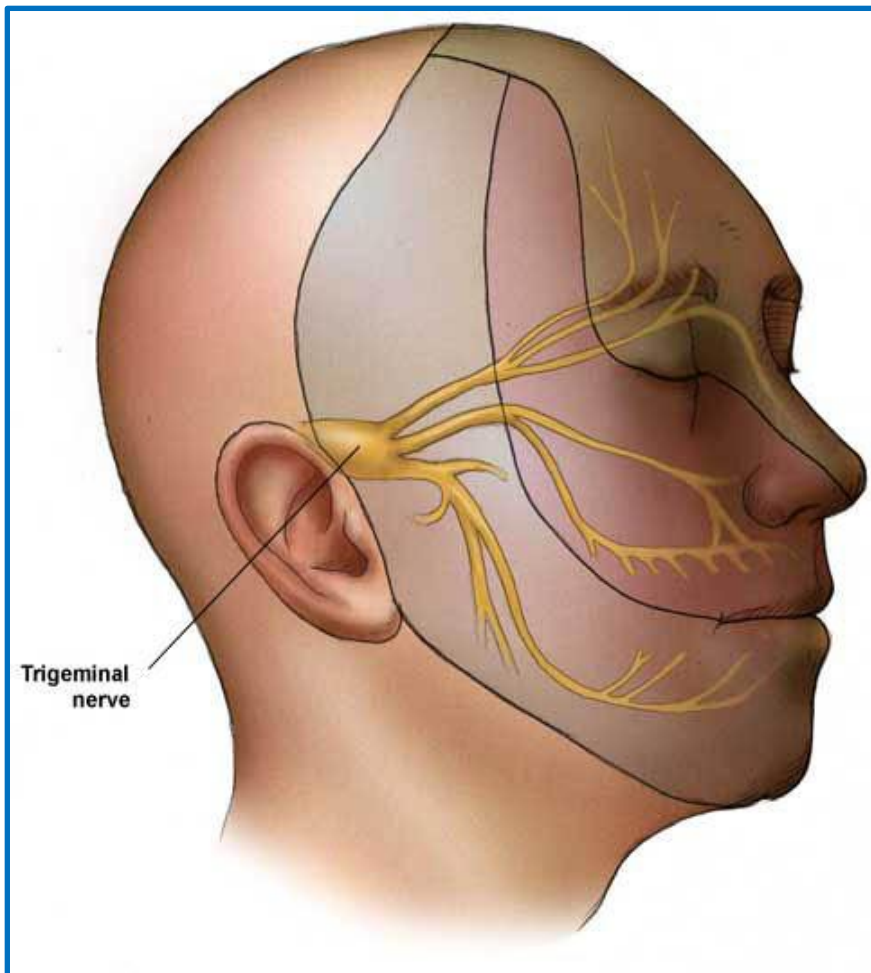
Blokada n. occipitalis

G 25

3 ml LA + kortikosteroid



Blokada n. Trigeminus-a



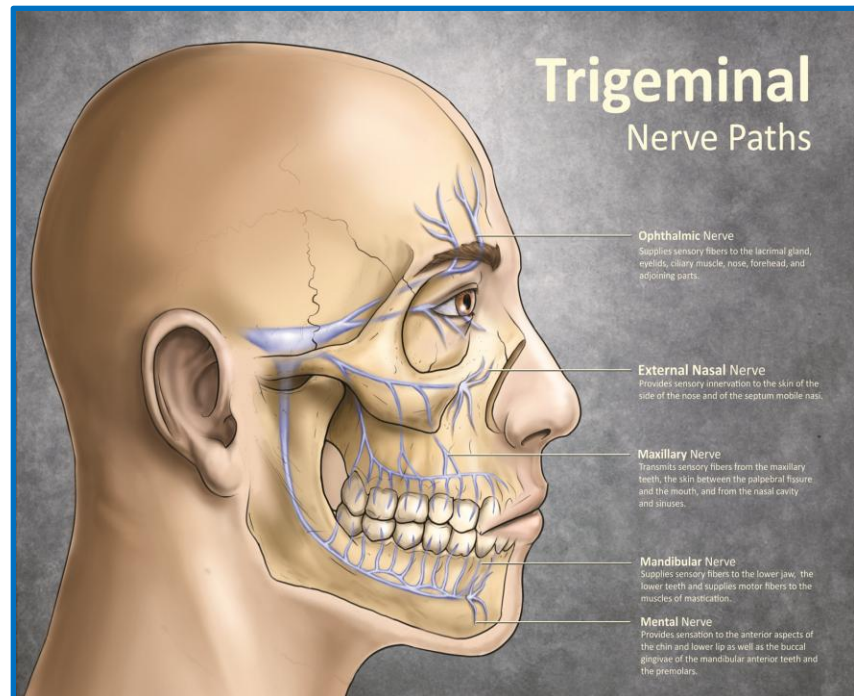
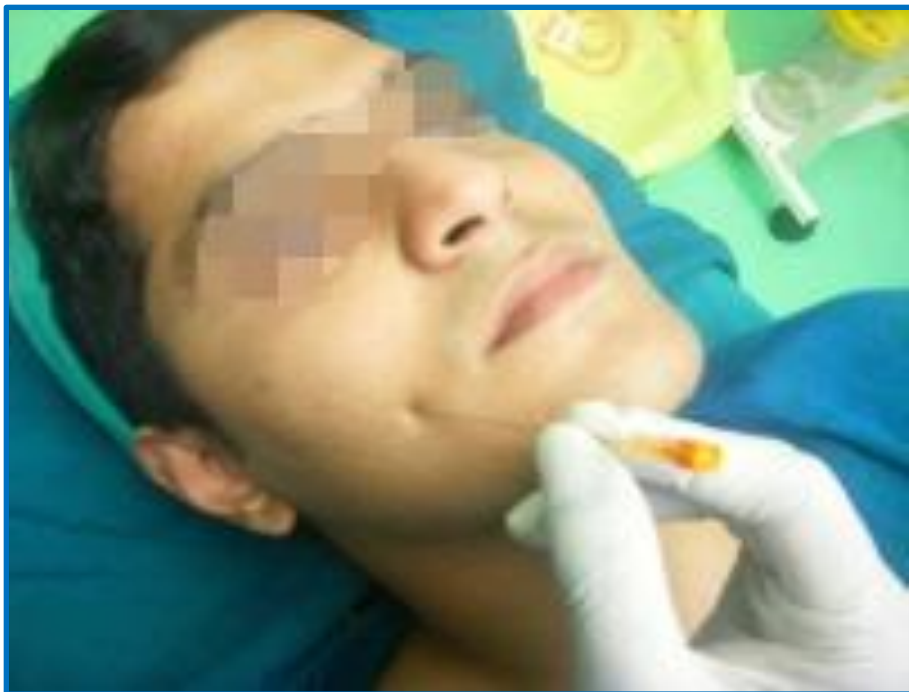Neuroliza:

100 % Glicerol – efekat 3-5 meseci

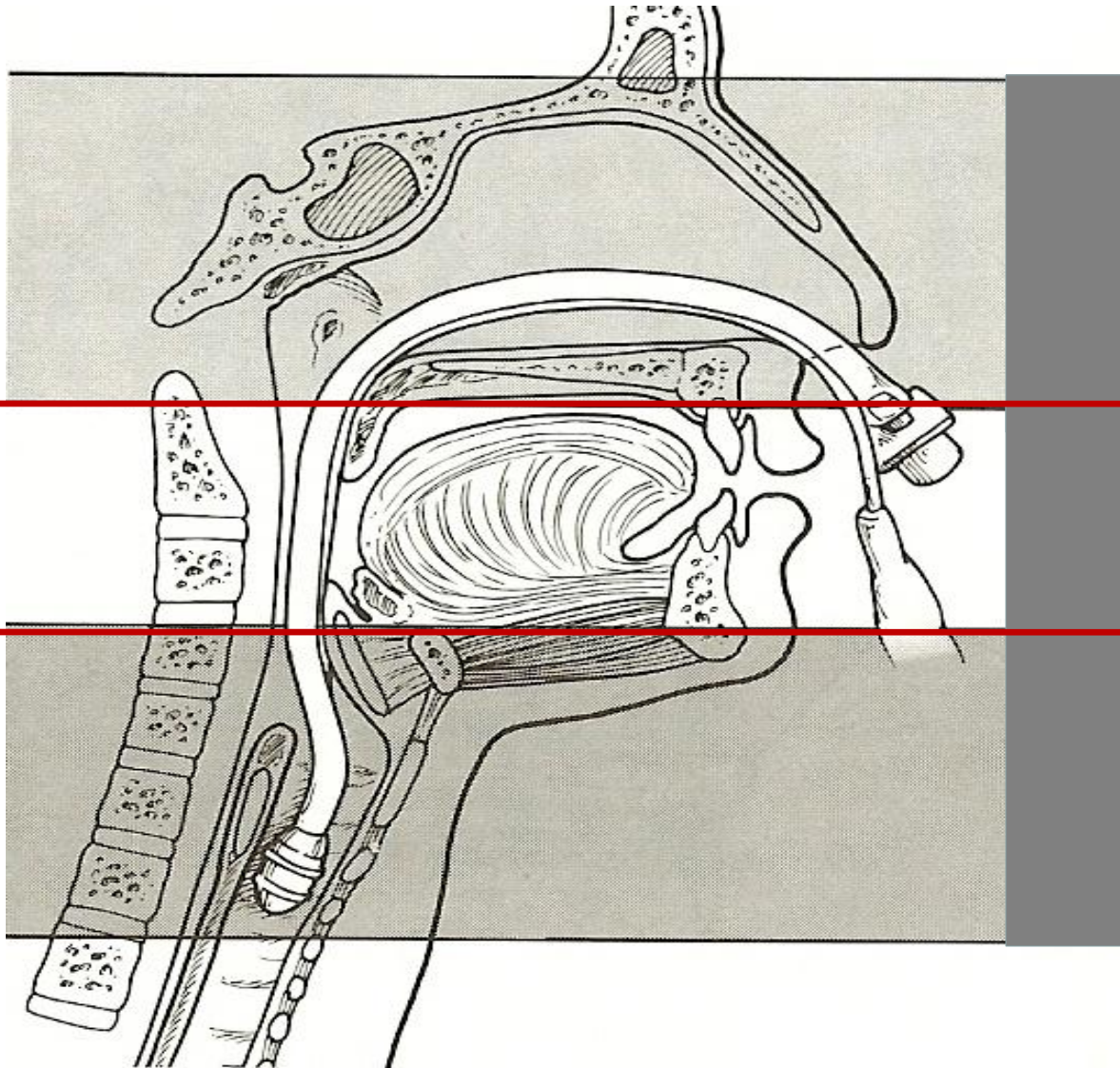
4-10 % Phenol

50-70 % Alkohol

Indikacije: neuralgija trigemina nepoznate etiologije
postherpetična neuralgija
posledica infiltracije tumora
kada su iscrpljene druge opcije lečenja



Inervacija disajnog puta



n. trigeminus

n. glossopharyngeus

n. vagus

Anestezija za obezbeđenje disajnog puta kod budnog bolesnika

Topikalna primena lokalnih anestetika 2-4 % Lidocaina

+

Glikopirolat 0,4 mg ili atropin 0,5 mg – 1,0 mg IM

Blokada nerava:

n. glossopharingeus
n. laringeus superior
n. laringeus recurens

Blokada n. glossopharyngeus-a

Peristiloidni pristup

Transoralni pristup

Arcus glossopalatinus

Senzorna inervacija:

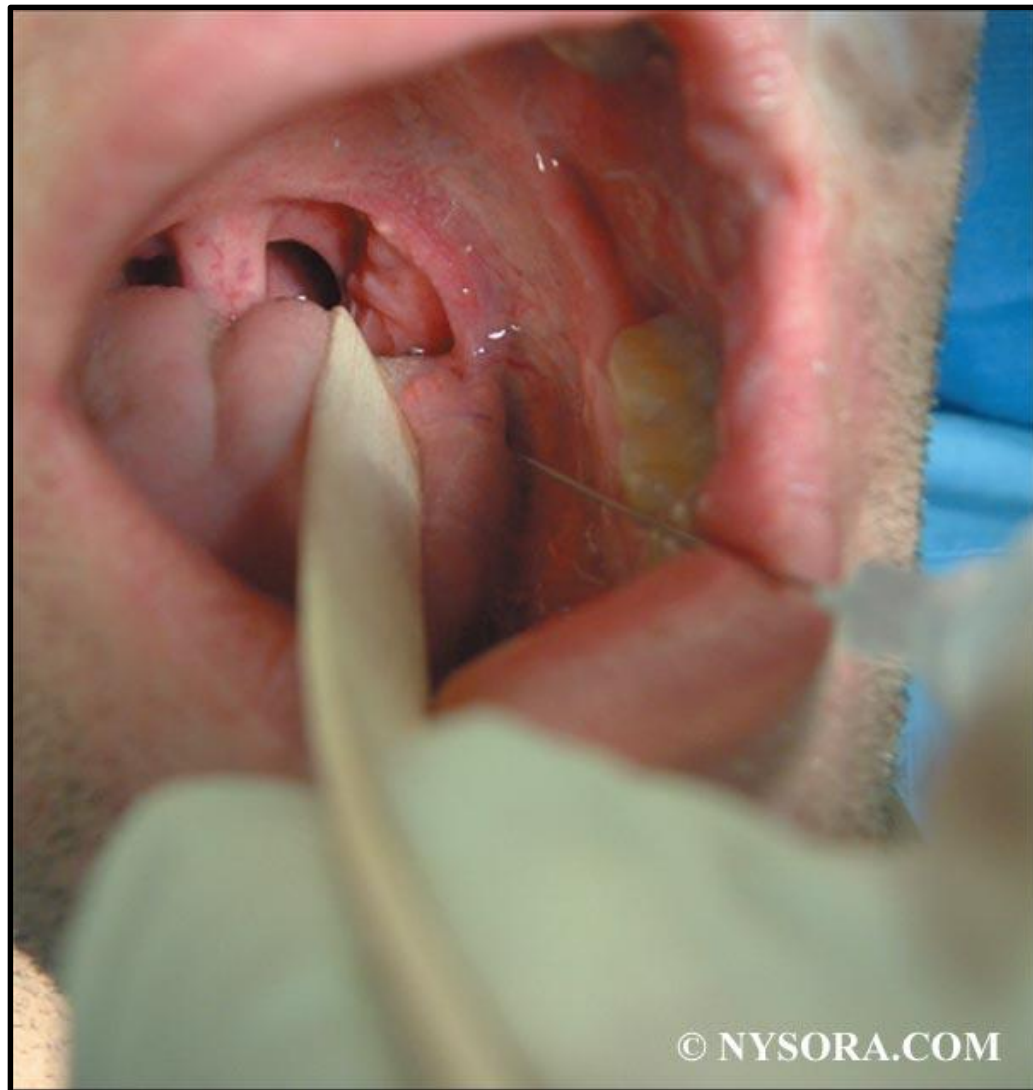Zadnji deo jezika

Orofarinx

Meko nepce

Epiglotis
(farinksna površina)

Blokada n. glossopharyngeus-a

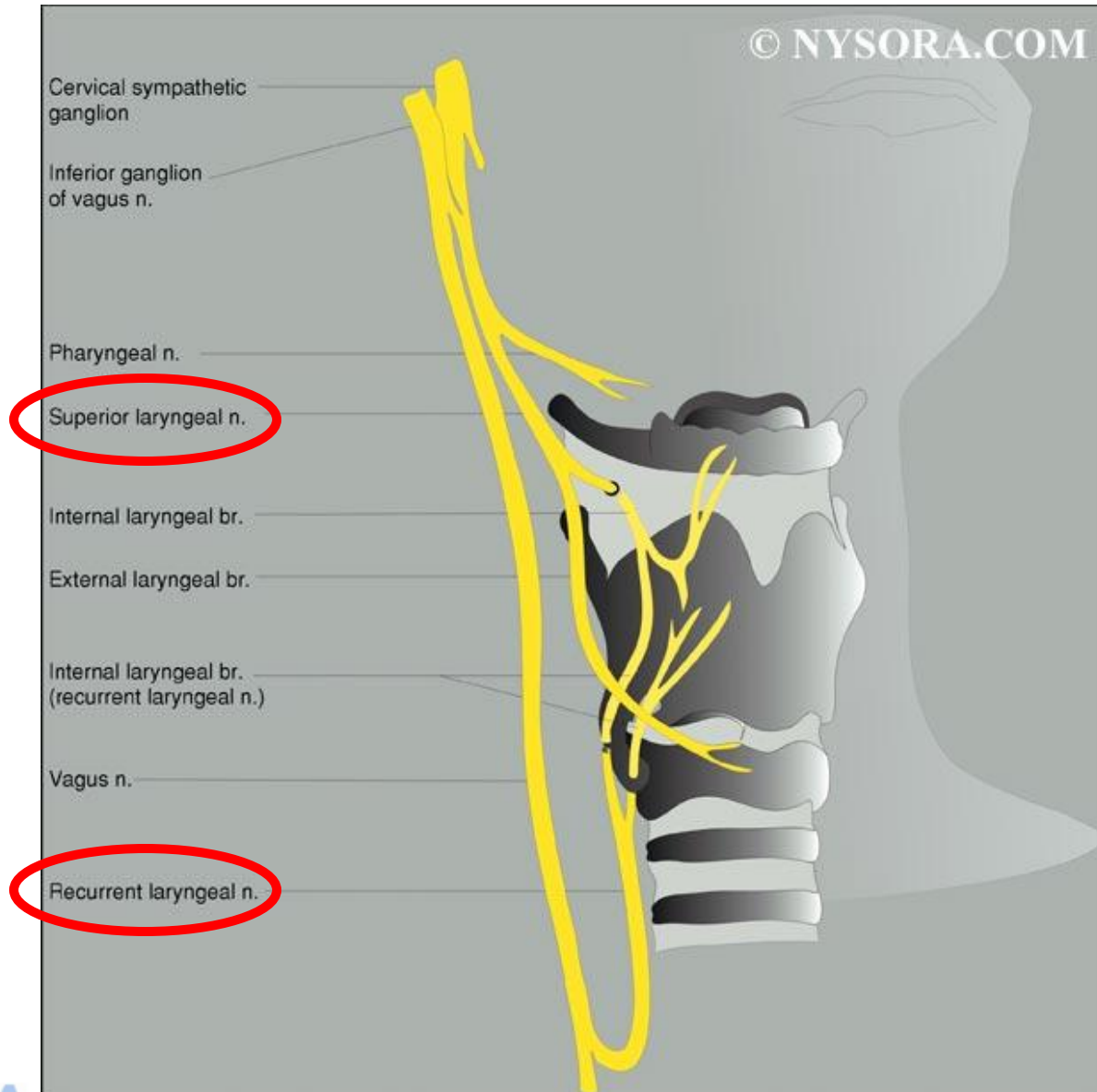


22 G igla

5 ml LA sa svake strane

Ne kao izolovani blok -
kombinacija sa drugim
blokom

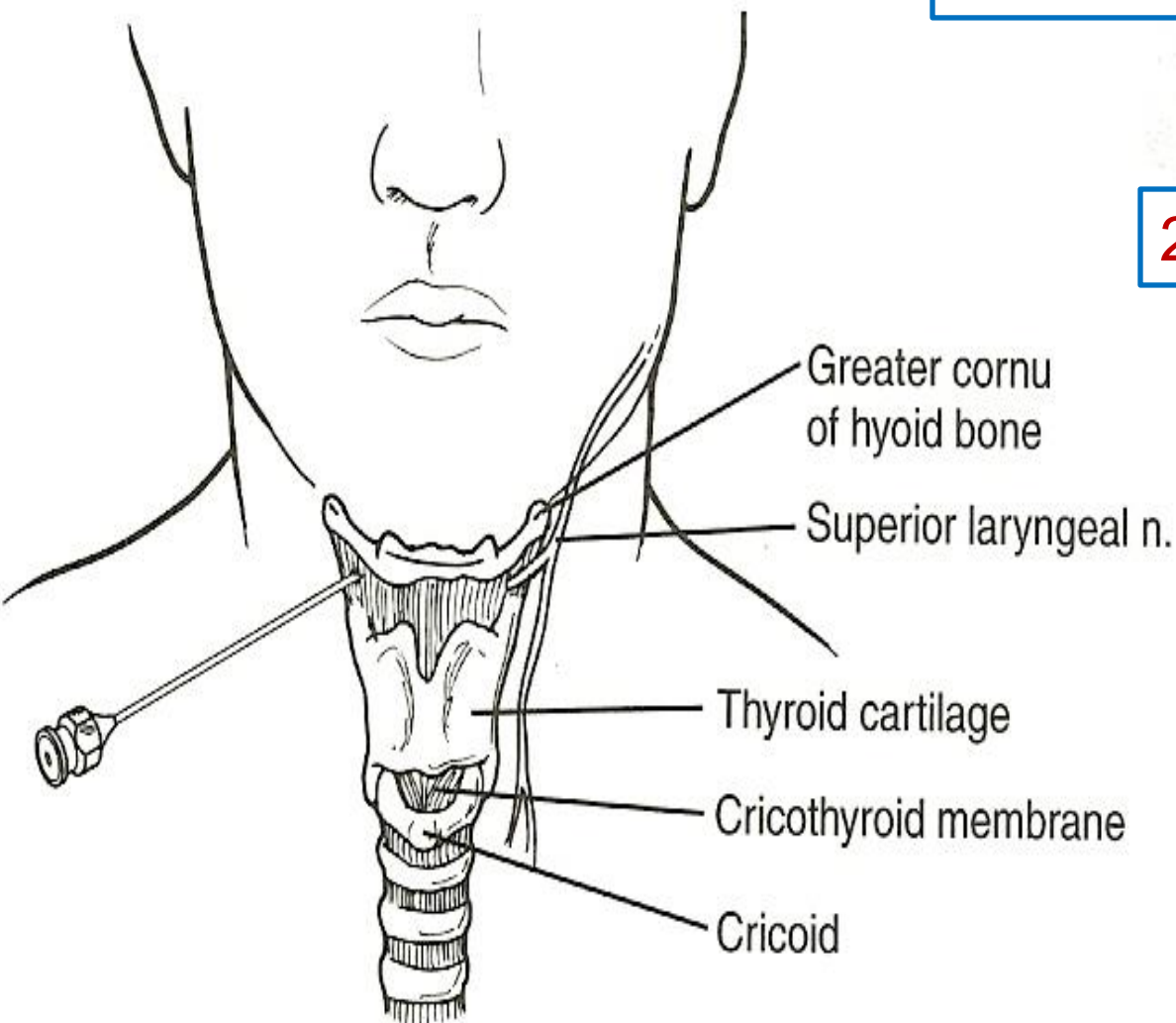
Inervacija larinx-a



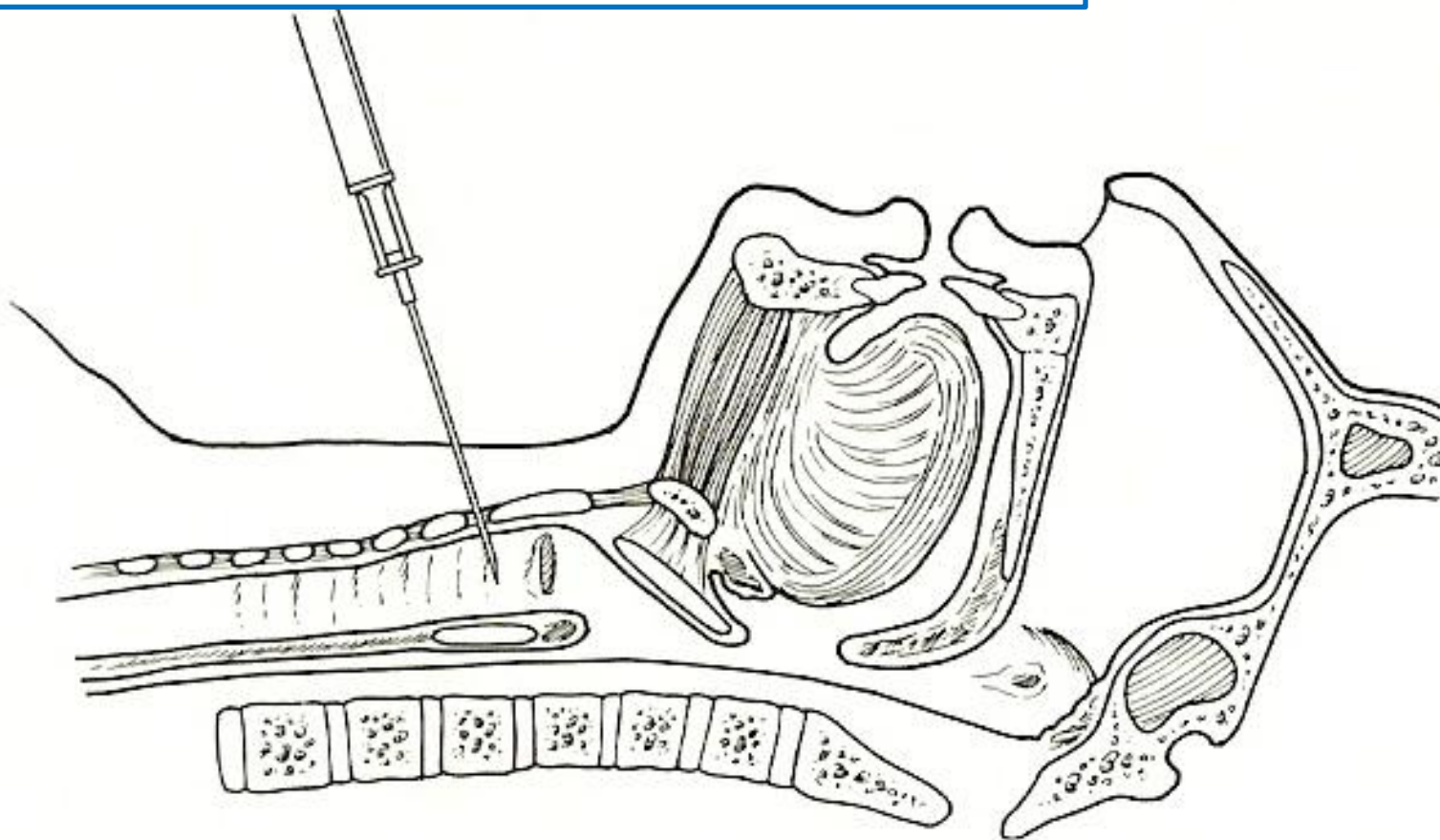
Blokada n. Laringeus superior

Veliki rog hioidne kosti

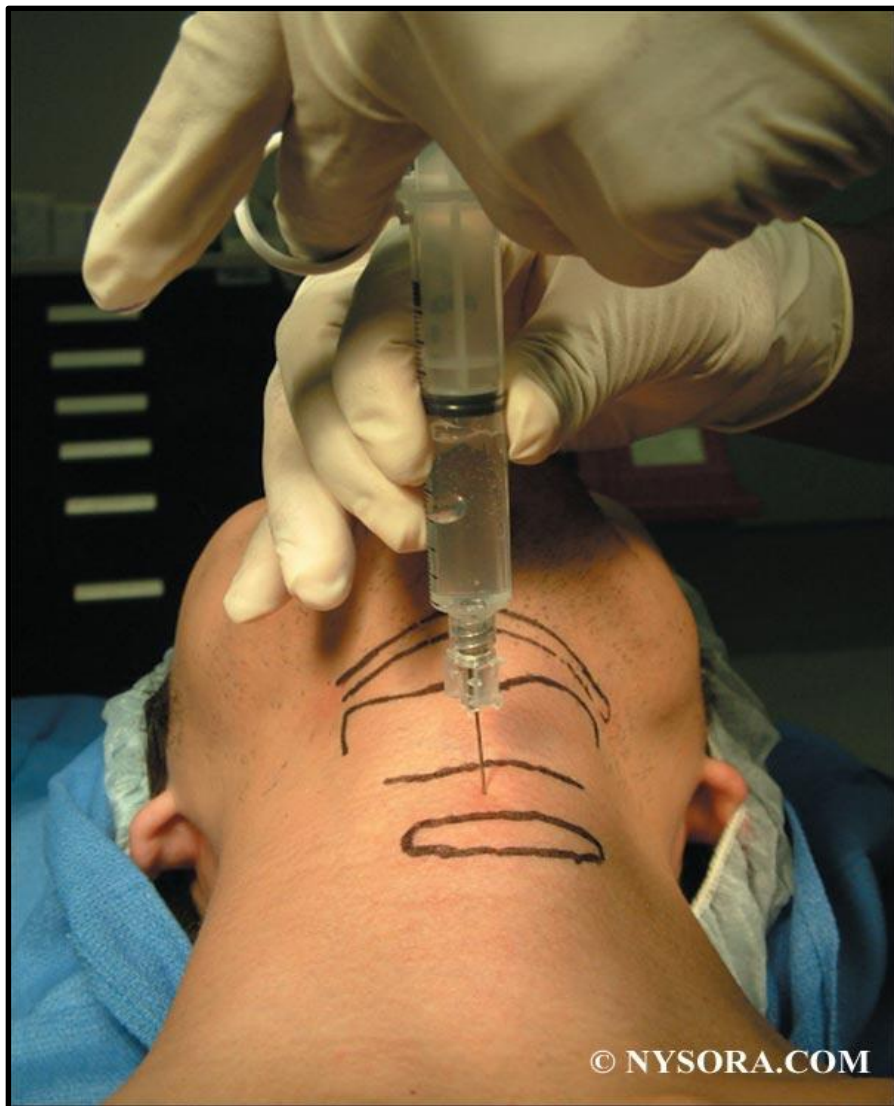2-3 ml 1-2% Lidocain



- Kroz krikotiroidnu membranu
- Blokira refleks kašlja



Blokada n. laringeus recurens



© NYSORA.COM

N. Laringeus recurens

➤ senzorna inervacija:

Glodne žice i traheja

MOTORNA FUNKCIJA INTAKTNA

SENZORNA BLOKADA

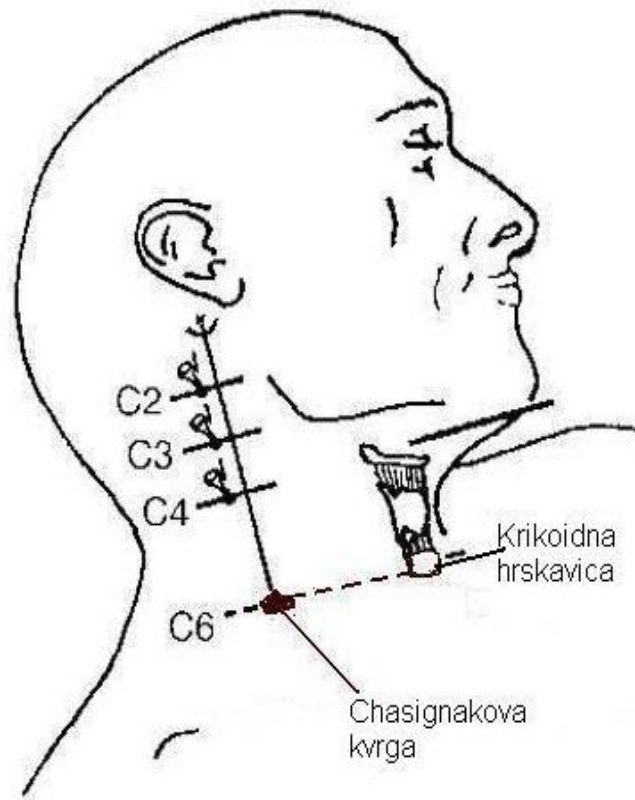
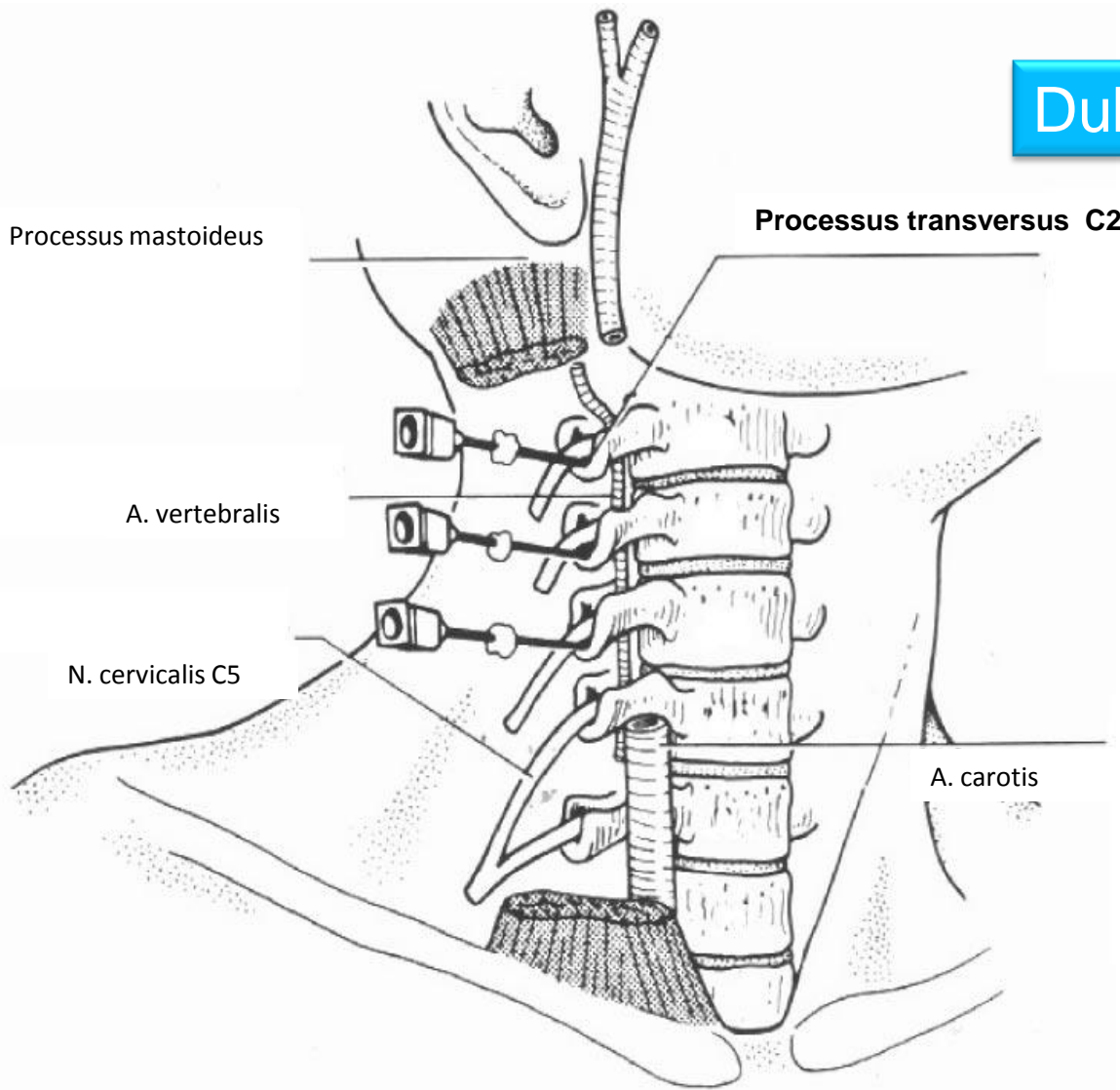
➤ Iгла 20 ili 22 G

➤ 2-4% Lidocain 4-5 ml

Awake Endotracheal Intubation (1).3gp

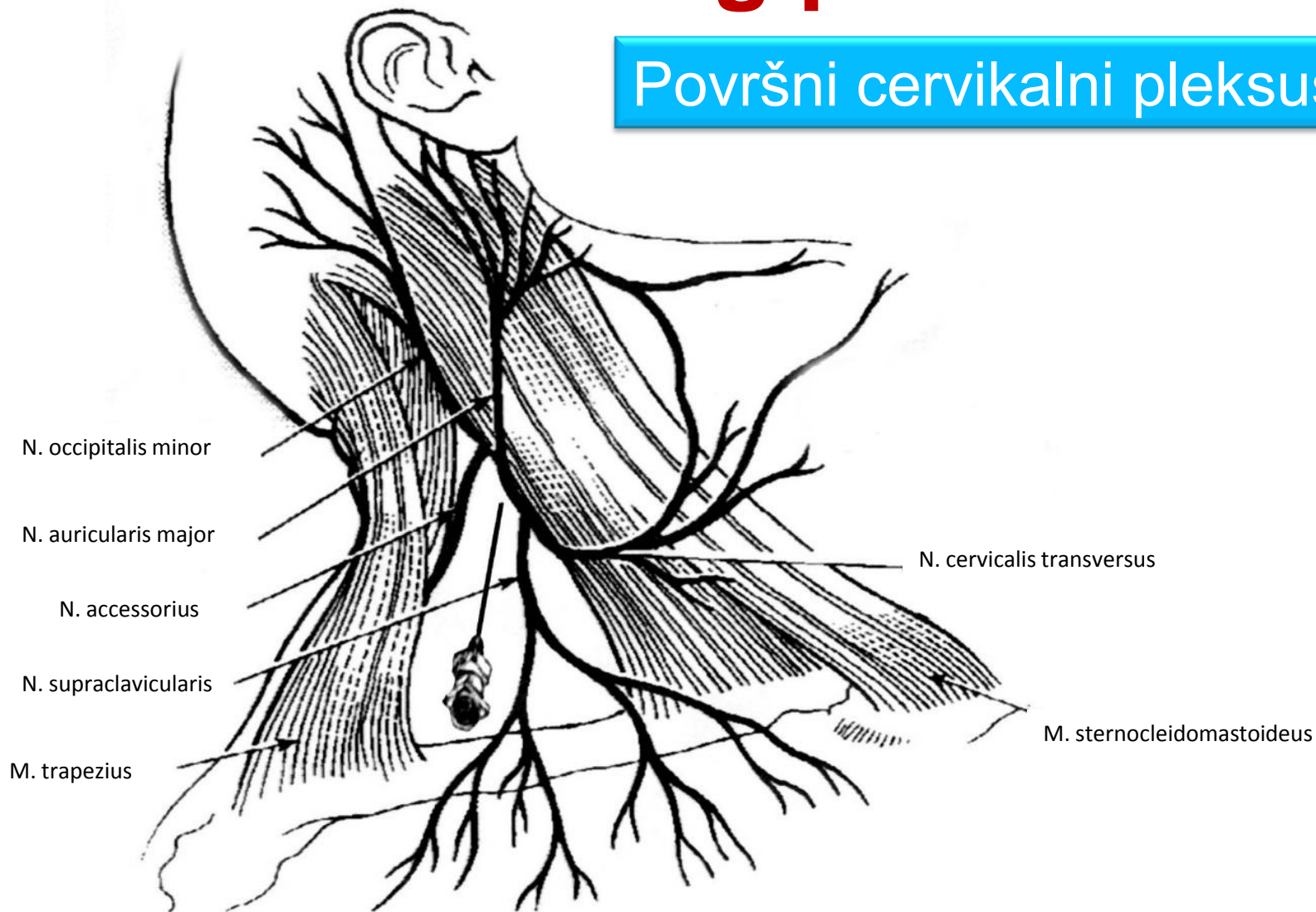
Blok cervikalnog pleksusa

Duboki cervikalni pleksus

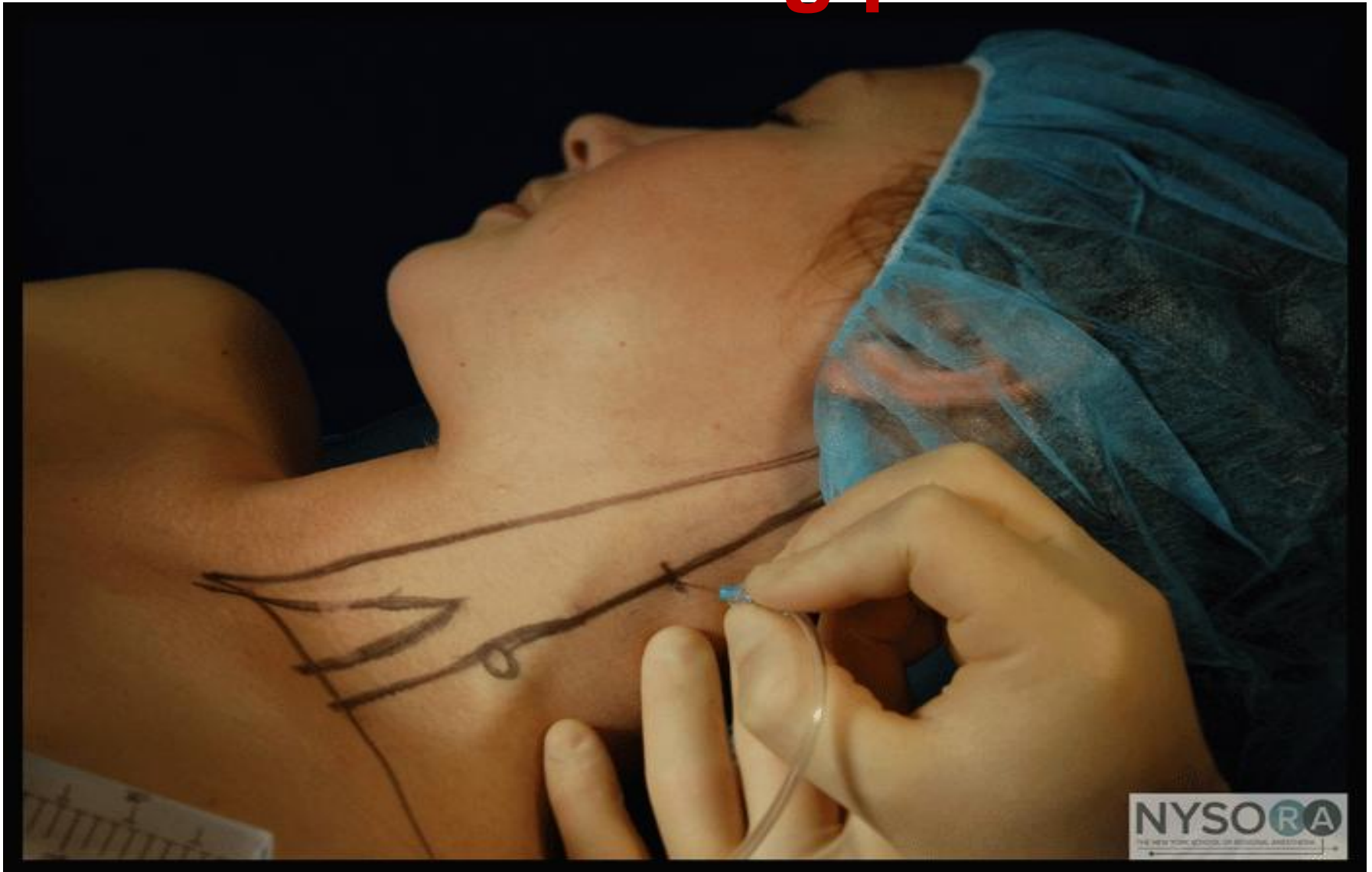

Blok cervikalnog pleksusa

Površni cervikalni pleksus



Blok cervikalnog pleksusa



Komplikacije cervikalnog bloka

- ✓ punkcija karotidne ili vertebralne arterije
- ✓ epiduralno/subarahnoidalno širenje bloka
- ✓ bilateralni blok freničnog nerva
- ✓ blok n.Laringeus recurens-a

HVALA NA PAŽNJI

